




## Ticked-Off Rash

Rakin Solaiman, MD, Jeff Kilcup, DO<sup>1</sup>, Samuel Josephsen, MD<sup>2</sup>, Kang Zhang, MD<sup>3</sup> 

<sup>1</sup> Department of Infectious Diseases, Wake Forest University School of Medicine,

<sup>2</sup> Department of Internal Medicine, Internal Medicine Residency,

<sup>3</sup> Department of Internal Medicine, Internal Medicine Residency Spokane

### Journal of Brown Hospital Medicine

Vol. 3, Issue 2, 2024

#### Article Information

Keywords: eschar, infectious disease, zoonotic infection, tularemia, tick borne illness

<https://doi.org/10.56305/001c.115728>

Submitted: December 18, 2023 EDT

Accepted: March 21, 2024 EDT

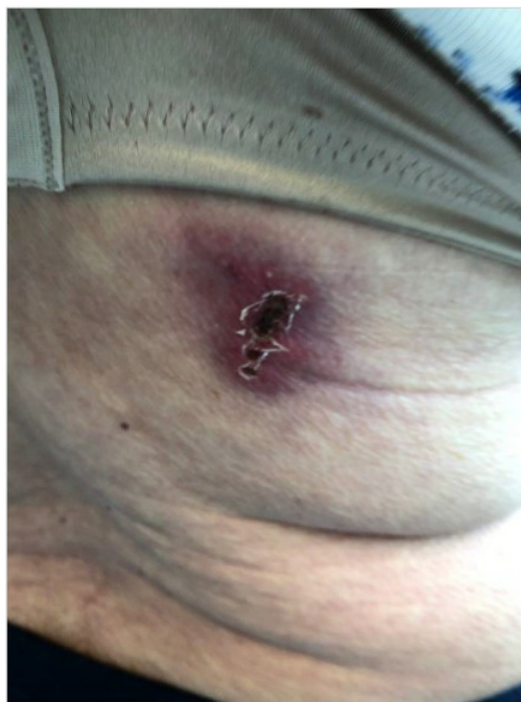#### TICKED OFF RASH

A previously healthy 89-year-old female presented to the emergency room with four months of fevers and an unintentional 20-pound weight loss without noted lymphadenopathy. Prior to her hospitalization, the patient was evaluated at an outpatient clinic for high-grade fever and rash ([Figure 1](#)), which was treated as non-purulent cellulitis. Routine laboratory workup was unremarkable aside from AST 62 U/L (normal 10-65 U/L). After several courses of outpatient antibiotic therapies, two 5-day courses of Cephalexin, and a 10-day course of double-strength Trimethoprim-Sulfamethoxazole, the rash disappeared. However, her fevers and weight loss persisted, and she developed acute thrombocytopenia (platelets 31 K/uL (normal 150-400 K/uL)). During day six of her hospitalization, blood cultures became positive for *Francisella tularensis*, which was confirmed via RT-PCR and direct fluorescent antibody testing. *Francisella tularensis* antibody IgM was noted to be greater than 100 U/mL (9 or less is negative, 16 or greater positive), and IgG 80 U/mL (9 or less is negative, 16 or greater positive). Subsequent targeted history revealed the patient had sustained a tick bite while camping near the Western Canadian border before developing the initial rash with central eschar. Infectious disease was consulted, and the patient showed marked improvement in clinical symptoms with a prolonged course of intravenous antibiotics.

Eschar formation is characterized by an adherent brown-black crust with cutaneous necrosis that warrants diagnostic investigation. This is especially true in cases refractory or non-responsive to typical therapies, given the life-threatening nature of the possible underlying etiologies.<sup>1</sup> A targeted history and physical exam should in-

#### Abstract

An 89-year-old female initially presented to outpatient clinic for systemic symptoms of high-grade fever, malaise and unintentional weight loss along with a rash that was presumed to be non-purulent cellulitis. After several courses of antibiotics, the patient's symptoms worsened and was eventually hospitalized. Blood cultures resulted positive for *Francisella tularensis*. After more history taking the patient noted that she was bit by a tick during a camping trip that resulted with the initial rash.



**Figure 1.** Erythematous lesion with a raised central black eschar

clude infectious and non-infectious causes ([Table 1](#)).<sup>1-3</sup> Between statewide reported cases from 2011 to 2019, the highest cases were recorded in Arkansas (374 cases, 20.4% total), followed by Missouri (13.1%), Oklahoma (11.9%), and Kansas (11.2%).<sup>4</sup> In this specific case, the patient's persistent fevers, despite appropriate antibiotics, raises concern for atypical infections, including necrotizing soft tissue infections, systemic bacterial infections, fungal infections, and zoonotic illnesses.

Tularemia is caused by the intracellular aerobic gram-negative bacteria *Francisella tularensis*, which can affect

**Table 1.** Differential diagnosis for Black Eschar Lesions

Infectious Etiologies	
Systemic Diseases	Ecthyma Gangrenosum
	Endocarditis with embolic phenomena
	Systemic Fungal Infections
Specific Zoonotic Disease	Cutaneous Anthrax (Bacillus Anthracis)
	Tularemia (Francisella tularensis)
	Plague (Yersinia Pestis)
	Rickettsial Illnesses
	<ul style="list-style-type: none"> <li>• South African Tick Typhus</li> <li>• Indian Tick Typhus</li> <li>• Mediterranean Spotted Fever</li> <li>• Rickettsialpox</li> <li>• Scrub Typhus</li> </ul>
Non-Infectious Etiologies	
Injuries / Post Operative Complications	Flap Necrosis/Pressure Ulcers/ Burns
Malignancy	Lymphomatoid Papulosis
Toxin Mediated	Snake / Spider Bites

both humans and a diverse population of animals. Tularemia can be transmitted by animals to humans (commonly rodents and lagomorphs) as well as arthropod bites (tick and deer fly bites being most common in the United States).<sup>5</sup> Additionally, *Francisella tularensis* can survive up to three months in water and six months in dry litter, and ingestion of contaminated foods and water sources or aerosolization of dry litter serves as opportunities for infection. *Francisella tularensis* is a category A bioterrorism agent; an infectious substance that, if exposure occurs, is capable of causing permanent disability, life-threatening, or fatal disease in otherwise healthy humans.<sup>6</sup> Tularemia presents as an acute febrile illness and has many unique clinical manifestations that depend upon the mechanism of infection including ulceroglandular, glandular, oculoglandular, oropharyngeal, gastrointestinal, pneumonic, and typhoidal tularemia.<sup>7</sup> The most common manifestation is ulceroglandular, which exhibits a characteristic skin lesion, as in our case. Diagnosing tularemia requires a high degree of suspicion. Screening for common risk factors, including animal interactions, ingestion of contaminated materials, or exposure to aerosolized litter in lawn mowing in endemic ar-

reas, may aid in identifying those to be tested. Tularemia diagnosis remains primarily based on history, clinical suspicion, and serological methods, but these tests are varied and poorly standardized.<sup>8</sup> Most commonly, diagnosis is confirmed with either an initial titer > 1:160 or a four-fold rise between initial and convalescent serology.<sup>8</sup> *Francisella tularensis* was incidentally found on blood culture and was confirmed with RT PCR and direct fluorescent antibody. Serologic studies should be performed only in patients in whom tularemia is a realistic possibility. *Francisella tularensis* is a  $\beta$ -lactamase producing bacteria, and the first line treatment consists of a 7–14-day course of either intravenous streptomycin or gentamicin. Fluoroquinolones and tetracyclines are alternative therapy options but are typically reserved for mild cases and may be associated with higher rates of relapse.<sup>5,7,9</sup>

### Author Contributions

All authors have reviewed the final manuscript prior to submission. All the authors have contributed significantly to the manuscript, per the International Committee of Medical Journal Editors criteria of authorship.

- Substantial contributions to the conception or design of the work; or the acquisition, analysis, or interpretation of data for the work; AND
- Drafting the work or revising it critically for important intellectual content; AND
- Final approval of the version to be published; AND
- Agreement to be accountable for all aspects of the work in ensuring that questions related to the accuracy or integrity of any part of the work are appropriately investigated and resolved.

### Disclosures/Conflicts of Interest

The authors report no financial conflicts of interest.

### Corresponding author

Kang Zhang, MD  
 Department of Internal Medicine  
 Spokane Teaching Health Center Spokane, WA, USA  
 Email: [kang.zhang@providence.org](mailto:kang.zhang@providence.org)



This is an open-access article distributed under the terms of the Creative Commons Attribution 4.0 International License (CCBY-NC-4.0). View this license's legal deed at <https://creativecommons.org/licenses/by-nc/4.0> and legal code at <https://creativecommons.org/licenses/by-nc/4.0/legalcode> for more information.

## REFERENCES

1. Dunn C, Rosen T. The rash that leads to eschar formation. *Clin Dermatol*. 2019;37(2):99-108. doi:10.1016/j.clindermatol.2018.12.003
2. McGinley-Smith DE, Tsao SS. Dermatoses from ticks. *J Am Acad Dermatol*. 2003;49(3):363-396. doi:10.1067/s0190-9622(03)01868-1
3. Aquino LL, Wu JJ. Cutaneous manifestations of category A bioweapons. *J Am Acad Dermatol*. 2011;65(6):1213.e1-1213.e15. doi:10.1016/j.jaad.2010.08.040
4. Bishop A, Wang HH, Donaldson TG, et al. Tularemia cases increase in the USA from 2011 through 2019. *Curr Res Parasitol Vector Borne Dis*. 2023;3(100116):100116. doi:10.1016/j.crpvbd.2023.100116
5. Feldman KA. Tularemia. *J Am Vet Med Assoc*. 2003;222(6):725-730. doi:10.2460/javma.2003.222.725
6. Maurin M. *Francisella tularensis* a potential agent of bioterrorism? *Expert Rev Anti Infect Ther*. 2015;13(2):141-144. doi:10.1586/14787210.2015.986463
7. Snowden J, Simonsen KA. Tularemia. In: *StatPearls*. StatPearls Publishing; 2023.
8. Maurin M. *Francisella tularensis*, Tularemia and Serological Diagnosis. *Front Cell Infect Microbiol*. 2020;10(512090). doi:10.3389/fcimb.2020.512090
9. Stevens DL, Bisno AL, Chambers HF, et al. Practice Guidelines for the Diagnosis and Management of Skin and Soft Tissue Infections: 2014 Update by the Infectious Diseases Society of America. *Clinical Infectious Diseases*. 2014;59(2):e10-e52. doi:10.1093/cid/ciu296